



## **Testicular Rescue Following D-ribose L-cysteine Administration on Torsion-detorsion Injury**

**Adunfe, O. O.<sup>1\*</sup>, Ubulu, L. U.<sup>2,3</sup>, Tokunbo, O. S.<sup>4</sup>, Adeleke, O. S.<sup>4</sup>, Iyiola, O. B.<sup>4</sup>, Oguntade, A. A.<sup>1</sup>, Babatunde, L. B.<sup>2</sup>, Ebukhaile, R. O.<sup>3</sup>, Abimbola, P. T.<sup>2</sup>, & Duru, F.<sup>2</sup>**

<sup>1</sup>*Department of Medical Laboratory Science, Fountain University, Osogbo, Osun State, Nigeria;*

<sup>2</sup>*Department of Anatomy, University of Lagos, Nigeria;*

<sup>3</sup>*Department of Human Biology, University of Cape Town, South Africa;*

<sup>4</sup>*Department of Anatomy, Osun State University, Osogbo, Osun State, Nigeria*

**\*Corresponding author:** [adunfe.oluwatobi@fuo.edu.ng](mailto:adunfe.oluwatobi@fuo.edu.ng); +2348160645738

### **Abstract**

**Background:** Testicular torsion is a urological emergency inducing irreversible ischemia and loss of organs. The damage intensity depends on the twisting severity and ischemia duration. Its treatment is surgery, after which 65% of its patients can still suffer from testes atrophy.

**Objectives:** The study investigated the effect of D-ribose L-cysteine on the cytoarchitecture of the testes after Torsion-detorsion injury. The study also investigated the effect of D-ribose L-cysteine on serum Malondialdehyde, Glutathione and Albumin after Torsion-detorsion injury.

**Methodology:** Thirty (30) adult male Wistar rats of about 180-220 g were procured from animal holding and divided into six groups (n=5). Group 1: control group, Group 2: negative control group and torsioned for one hour. Groups 3 to 6: treated groups induced with torsion for one hour and treated with Riboceine for different hours (Group 3: treated with Riboceine for one hour, Group 4: treated with Riboceine for one hour thirty minutes, Group 5: treated with Riboceine for two hours and Group 6: treated with Riboceine for two hours thirty minutes). All the experimental rats across the groups were sacrificed to determine the effect of torsion-detorsion injuries and check for ameliorative roles of d-ribose l-cysteine on the testes using biochemical tests (Serum Malondialdehyde, Glutathione and Albumin) and histological techniques (routine hematoxylin and eosin stain). **Results:** Torsion-detorsion increased serum Malondialdehyde levels causing accumulation of oxidative stress, decreased serum Glutathione and Albumin levels, and some testicular injuries such as damage to seminiferous tubules, interstitial oedema, and vascular congestion. The D-ribose L-cysteine reserved testicular atrophy following torsion detorsion injury.

**Conclusion/ Recommendations:** D-ribose L-cysteine ameliorates increased serum Malondialdehyde an indicator of oxidative stress which affects sperm quality and function. Glutathione has a stimulatory effect on the male reproductive hormones and potentially boosts male fertility. This study recommends oral intake of D-ribose L-cysteine for restoring the cytoarchitecture of the testes after torsion-detorsion injury and increasing sperm quality.

**Keywords:** Infertility, Testes, Cytoarchitecture, Glutathione, Histological techniques.

## **Introduction**

Testicular torsion is a urological emergency that can result in irreversible ischemia and the loss of organs. Its occurrence is relatively rare, with a prevalence of 1 in 4000 men under 25, and a significant proportion, around 61%, affected by this condition are under 21 years old (Mirhoseini et al., 2017). Diagnosing and treating testicular torsion promptly is crucial, as any delay can lead to testicular damage and negatively impact fertility. Infertility is a major health concern, with approximately 50% of cases attributed to male factors such as sperm disorders, hormone or pituitary gland problems, environmental and lifestyle factors (Mirhoseini et al., 2017). The extent of damage depends on the severity of twisting and the duration of ischemia. Surgical intervention is the primary method for treating testicular torsion. Unfortunately, roughly 65% of patients still experience testicular atrophy even after surgery. Furthermore, testicular torsion has been shown to decrease total antioxidant levels while increasing total oxidants and the oxidative stress index (Mirhoseini et al., 2017). If treated within a few hours of diagnosis or observation, the testicle can then be saved; waiting longer than necessary can cause permanent damage resulting in infertility (Olugbenga et al., 2012). When blood flow has been cut off more than 12 hours, a testicle may become so damaged that it must be removed (Olugbenga et al., 2012). One of the most commonly selected animals for studies in experimentally induced testicular torsion orchiectomy and cryptorchidism is the rat (Akan et al., 2015). The main pathophysiology of testicular torsion is ischemic reperfusion injury of the testis caused by the twisted spermatic cord and its release (Olugbenga et al., 2012), most likely mediated by oxygen free radicals (Akan et al., 2015).

D-ribose-l-cysteine is a critical component for maintaining healthy fertility in humans, deserving our attention (Dare et al., 2017). Antioxidants, which encompass a group of vitamins, minerals, and other nutrients, play a vital role in safeguarding the body from the harm

caused by free radicals (Dare et al., 2017). They act as a protective system, neutralising the harmful effects of free radicals. The active ingredient in riboceine is D-ribose-l-cysteine (Dare et al., 2017). When it comes to glutathione, simply consuming as a whole is ineffective because it gets broken down during digestion before reaching the cells. The ribose component in the riboceine effectively overcomes this challenge by safeguarding and delivering the delicate cysteine molecule, allowing cells to precisely generate glutathione when mostly needed (Falana et al., 2017). L-cysteine is often referred to as a semi-essential amino acid because humans can synthesize it from the amino acid methionine. In addition to forming various proteins, L-cysteine is a precursor to glutathione, which plays a pivotal role in detoxifying cellular oxidative stress (Adelakun et al., 2018). Elevated levels of oxidative stress can potentially hinder cellular glucose metabolism through multiple mechanisms, including redox imbalances and insulin resistance (Adelakun et al., 2018). This study aimed to explore the numerous benefit of oral intake of D-ribose L-cysteine supplements due to absence of adequate literature on torsion-detorsion injury.

## **Material and methods**

### *Procurement of riboceine*

Riboceine, which contains D-ribose l-cysteine, was obtained from the Department of Anatomy, College of Medicine, University of Lagos.

### *Experimental design*

A total of 30 adult male Wistar rats, weighing approximately 180-220 grams, were obtained from an animal holding facility. These rats were divided into six groups, each consisting of five (5) rats. Group 1 was the control group, while groups 2 to 6 were the treated groups. The rats were housed in a well-ventilated room and kept in plastic cages within the animal facility of the Department of Anatomy, College of Medicine, University of Lagos, Idi Araba. They were acclimatized for two weeks under standard laboratory conditions, with a temperature range of 27-30°C. Lighting conditions mimicked

natural daylight, giving the rats approximately 12 hours of light and 12 hours of darkness daily.

The rats were provided with a diet of standard rat pellets and unrestricted access to tap water ad libitum. All experimental procedures complied with the guidelines set forth by the Health Research and Ethics Committee (HREC) of the College of Medicine, University of Lagos. Testicular torsion was created by rotating the right testicles in the counterclockwise direction along their longitudinal axis 720 degrees from the initial position and placed in the scrotum. Torsion was maintained in position by fixing the testis to the scrotum and suturing for one hour before 30 mg/kg of d-ribose l-cystein (Dare et al., 2017) was administered. Then orchietomy was performed, and tissues immediately fixed in Modified Davidson fluid. All surgical procedures were performed under 5 mg/kg of Ketamine anesthesia (Mirhoseini et al., 2017). Group 1 rats were not induced with testicular torsion. Group 2 rats were induced with 720 degrees testicular torsion of the right testis for one hour and then sacrificed. Group 3 rats were induced with 720 degrees testicular torsion of the right testis for one hour, detorsioned, treated with d-ribose l-cysteine for an hour, and then sacrificed. Group 4 rats were induced with 720 degrees testicular torsion of the right testis for one hour, detorsioned, treated with d-ribose l-cysteine for 1 hour 30 mins, and then sacrificed. Group 5 rats were induced with 720 degrees testicular torsion of the right testis for one hour, detorsioned, treated with d-ribose l-cysteine for 2 hours, and then sacrificed. Group 6 rats were induced with 720 degrees testicular torsion of the right testis for one hour, detorsioned, treated with d-ribose l-cysteine for 2 hours 30 mins, and then sacrificed.

#### *Animal sacrifice and sample collection*

The animals were sacrificed using cervical dislocation, the abdominal regions were excised, and the testes were removed from the sac and blotted out of fats before fixing in Modified Davidson fixative. Blood was collected from the apex of the heart via cardiac puncture.

#### *Histology examination*

The standard histological processing procedure involved Hematoxylin and Eosin staining. The testicular tissue samples were initially fixed and subsequently dehydrated using increasing concentrations of alcohol. Afterward, they were cleared in xylene and briefly immersed in molten paraffin wax. The samples were then embedded in molten paraffin wax to create solid blocks, which were then sliced into sections of 4µm thickness using a rotary microtome. The obtained sections were placed in a water bath at 40°C and then transferred onto glass slides. The sections were stained with Hematoxylin and Eosin to enhance visibility and contrast. Finally, the prepared slides were examined using a light microscope at 200x magnification, and photomicrographs were captured for further analysis. They were labelled plates 1 to 6.

#### *Statistical analysis*

The data of histological examination and biochemical parameters in Wistar rats was subjected to statistical analysis to determine any correlations among the results using GraphPad Prism software version 6.0. The results were presented as Mean ± SEM (Standard Error of Mean), with statistical significance evaluated at a p-value of less than 0.05. This analysis utilised One-way ANOVA and Tukey Post Hoc Tests to compare the various parameters' mean across the groups.

#### **Results**

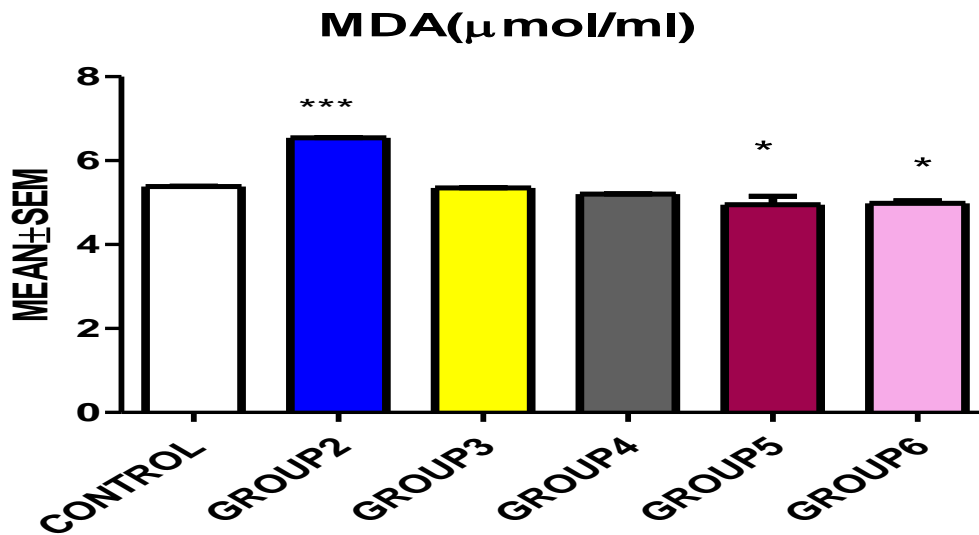
Comparison between the control and experimental groups on the Malondialdehyde level, group 2 rats showed increased MDA levels (\*\*p<0.0001), groups 3 and 4 rats showed a decrease in their MDA levels but were not statistically significant. In contrast, groups 5 and 6 showed a slight decrease in their MDA levels, which was statistically significant (\*p<0.05) (Chart 1). A comparison between the control and experimental groups was made on Glutathione levels; Group 2 rats showed increased GSH levels (\*\*p<0.0001). Groups 3, 4, 5, and 6 rats showed decreased GSH levels (\*\*p<0.0001) (Chart 2). A comparison between the control and

experimented groups' serum albumin level Showed that the group 2 rats had a decreased serum albumin level (\*\*p<0.0001). Groups 3, 4, 5, and 6 rats showed increased GSH levels (\*\*p<0.0001) (Chart 3).

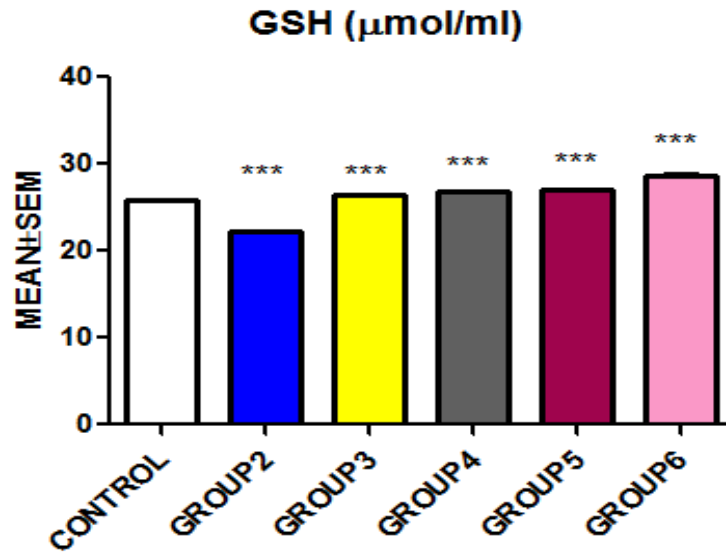
Photomicrograph of the testis of Group 1 showing normal testicular cytoarchitecture. The germinal epithelium, interstitial cells, and sperm cell layers appeared normal, and matured Spermatozoa were present in the lumen. The group 2 photomicrograph showed degeneration and disorientation of the sperm cell layers, germinal epithelium, premature release of spermatozoa into the lumen of the seminiferous tubules and interstitial edema (Red arrow: interstitial edema, yellow arrow: spermatocytes, blue arrow: spermatozoa, black arrow: spermatogonia, green arrow: germinal epithelium, L: lumen of seminiferous tubules). Photomicrograph of group 3 testis showed areas

with atrophied seminiferous tubules, vacuolisation of Leydig cells of the interstitium release of premature spermatozoa into the lumen, and degeneration of spermatogenic cell layers were observed (Red arrow: interstitium, yellow arrow: spermatocytes, blue arrow: spermatozoa, black arrow: spermatogonia, green arrow: germinal epithelium, L: lumen of seminiferous tubules S: Seminiferous tubules).

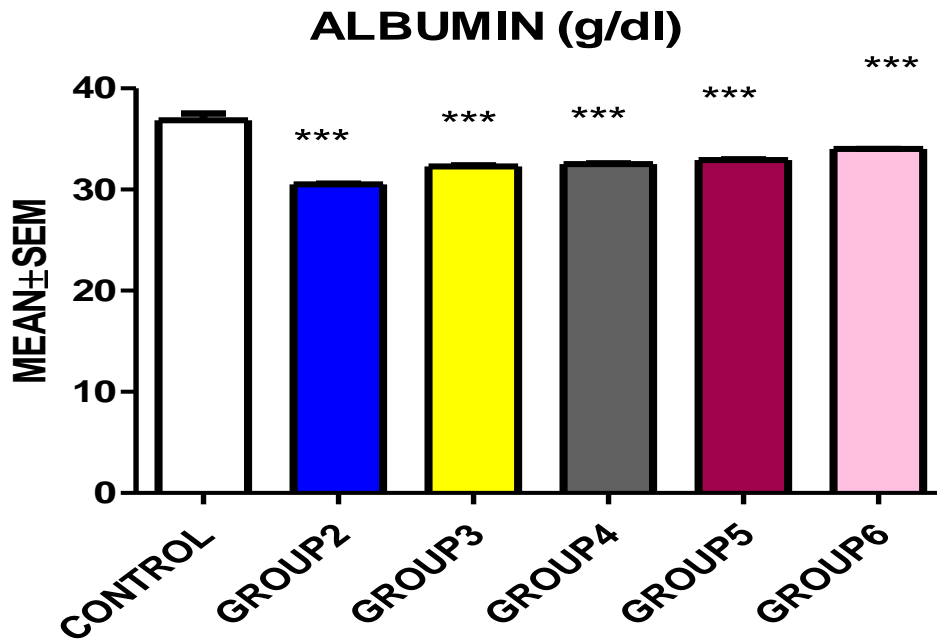
The group 4 testis were observed with a trace of mild damage to the seminiferous tubules, including interstitial oedema and vascular congestion. Spermatogenic cellular arrangement from spermatogonia to spermatid layer (outside to inside) was preserved (Red arrow: interstitium, yellow arrow: spermatocytes, blue arrow: spermatozoa, black arrow: spermatogonia, green arrow: germinal epithelium, L: lumen of seminiferous tubules, S: Seminiferous tubules).



Bar Chart 1: Comparison between the control and experimented groups' MDA level. \*: p<0.05, \*\*\*p<0.0001.



Bar Chart 2: Comparison between the control and experimented groups' GSH level. \*\*\*: p-value<0.0001.



Bar chart 3: Comparison between the control and experimented groups' serum albumin levels. \*\*\*: p-value<0.0001.

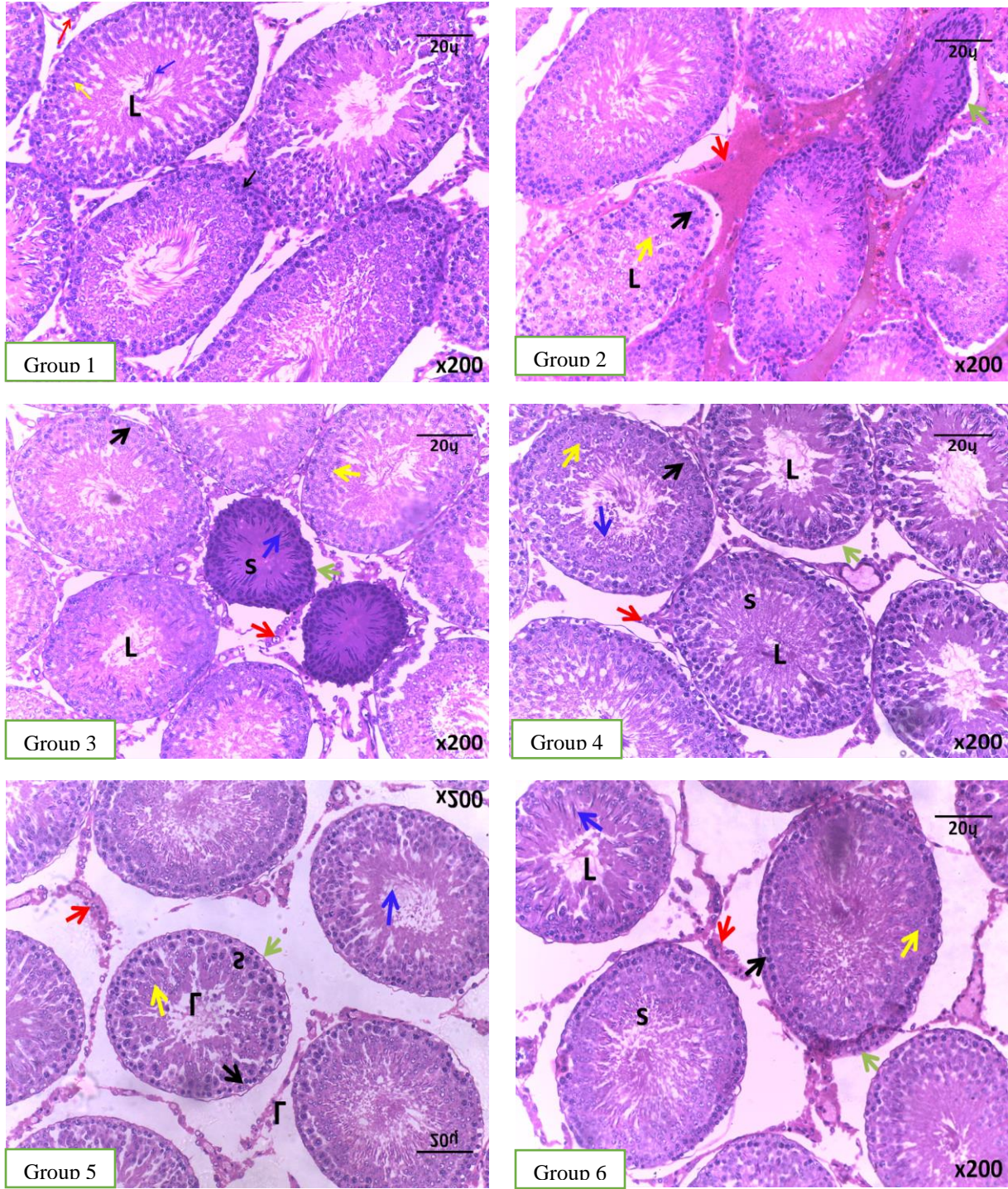


Plate 1: Photomicrograph of the testis of groups 1 to 6.

In the group 5 testis, the seminiferous tubules had no sign of alterations; however, congestion of blood vessels and mild interstitial edema were observed. The lumen was filled with matured spermatozoa, with no degeneration of the spermatogonia, Sertoli cells, and primary spermatozoa of the seminiferous tubules. The Leydig cells appeared euchromatic (Red arrow: interstitium, yellow arrow: spermatocytes, blue arrow: spermatozoa, black arrow: spermatogonia, green arrow: germinal epithelium, L: lumen of seminiferous tubules, S: Seminiferous tubules). The photomicrograph of group 6 showed that the sperm cell layers and germinal epithelium were preserved, while the Leydig cells appeared normal (Red arrow: interstitium, yellow arrow: spermatocytes, blue arrow: spermatozoa, black arrow: spermatogonia, green arrow: germinal epithelium, L: lumen of seminiferous tubules, S: Seminiferous tubules).

### **Discussion**

In this study, it was observed that testicular torsion without treatment, as in group 2 experimental rats, led to increase Malondialdehyde levels, and this observation agrees with the work of Mirhoseini et al. (2017), who also observed that testicular torsion without adequate treatment increased oxidative stress markers in the body. The observed increase in MDA level might result from the continuous production of free radicals, which leads to the accumulation of oxidative stress, thereby increasing the number of oxidative stress markers in the body.

This present study also observes that treatment of L-cysteine d-ribose after torsion-detorsion tends to reduce the Malondialdehyde level and increase the Glutathione level of the treated animals. The observed changes in the oxidative stress markers might result from the protective function and the ability of L-cysteine d-ribose to increase the production of glutathione in the body (Dare et al., 2017). Glutathione is generally produced in the body but reduces as one ages or sustains an injury or is diseased (Ikebuaso et al.,

2012). Riboceine is a synthetic antioxidant that helps to produce glutathione on demand. Riboceine helps to deliver cysteine directly to the cells, thereby increasing the production of glutathione in the testicular cells, which increases the GSH level (Osinubi et al., 2018).

In the study conducted by Kent et al. (2015), it was reported that serum albumin is important in rat testis because this protein is the principal carrier for testosterone in the plasma and interstitial fluid of this species. This present study observed that torsion-detorsion injury without treatment reduced serum albumin levels, which may lead to reduced testosterone levels in the affected animals, leading to infertility. It was also observed that administration of L-cysteine d-ribose to treat torsion-detorsion led to increased serum albumin levels, which may help treat male infertility problems.

This present study agrees with Olugbenga et al. (2012), who observed that torsion-detorsion injury leads to testicular oedema and the disorientation of the sperm cell layers, atrophied seminiferous tubules, and other damage to testicular integrity. This present work also observed that treatment of torsion-detorsion injury with L-cysteine d-ribose was able to ameliorate it probably because of the action of L-cysteine, which increases the glutathione production to help return and preserve testicular integrity.

### **Conclusion and recommendations**

The study investigated managing testicular torsion in humans; discovered effective therapies for improving or salvaging a tormented testis; showed an improvement in serum albumin, MDA, and GSH levels in the tortured animal model treated with L-cysteine d-ribose; and discovered that L-cysteine d-ribose would potentially benefit the management of testicular torsion.

Therefore, the study recommends oral intake of D-ribose L-cysteine as it is not only beneficial in restoring the cytoarchitecture of the testes after torsion-detorsion injury but also increases sperm quality. Also more work should be done on

testicular torsion-detorsion injury, as understanding and discovery of many other drugs to treat this injury can significantly delay further testicular damage in the interval between the beginning of testicular ischemia and surgery. This way, the number of testes salvaged will increase.

### **Professional implications of the study**

*Early diagnosis and treatment:* The study underscores the urgency of diagnosing and treating testicular torsion promptly to prevent irreversible ischemia and organ loss. This highlights the importance of raising awareness among healthcare professionals and the public to recognize the symptoms and seek immediate medical attention.

*Potential therapeutic interventions:* The findings suggest that D-ribose L-cysteine has a protective effect against testicular atrophy and oxidative stress following torsion-detorsion injury. This opens up new avenues for therapeutic interventions aimed at improving patient outcomes post-surgery.

*Surgical outcomes:* Despite surgical intervention being the standard treatment, the study indicates that a significant number of patients suffer from testicular atrophy. Incorporating D-ribose L-cysteine as an adjunct therapy could potentially enhance surgical outcomes and reduce the incidence of atrophy.

*Oxidative stress management:* The study highlights the role of oxidative stress in testicular damage and the potential of antioxidants like D-ribose L-cysteine in mitigating these effects. This could lead to broader applications in managing oxidative stress-related conditions in urology and beyond.

*Male fertility enhancement:* By demonstrating that D-ribose L-cysteine improves sperm quality and male reproductive hormones, the study suggests that this compound could be beneficial in enhancing male fertility. This could have implications for fertility treatments and reproductive health management.

### **Limitations to the study**

*Limited sample size:* The study was conducted on only 30 adult male Wistar rats. This small sample size may not provide enough data to generalize the findings to a larger population or different species, including humans.

*Animal model:* While Wistar rats are commonly used for biomedical research, the results from animal models do not always directly translate to human biology. There may be significant differences in how humans respond to the treatment compared to rats.

*Duration of treatment:* The study only examined the effects of D-ribose L-cysteine over a relatively short period (up to two and a half hours). Long-term effects and the potential for chronic treatment were not investigated, which limits the understanding of the treatment's efficacy and safety over extended periods.

*Lack of clinical trials:* The study did not include clinical trials on human subjects. Without clinical trials, it's difficult to ascertain the safety, appropriate dosages, and effectiveness of D-ribose L-cysteine in humans with testicular torsion.

*Controlled environment:* The controlled environment of a laboratory setting does not account for the variability and complexity of real-world conditions. Factors such as underlying health conditions, age, genetic differences, and other variables were not considered, which may impact the treatment's effectiveness in a broader population.

### **Ethical approval**

Ethical approval was obtained from The Health Research Ethics Committee (HREC) of the College of Medicine, University of Lagos (CMUL) with reference number CMUL/HREC/0784/19

### **Acknowledgments**

The authors will like to appreciate the Department of Anatomy, University of Lagos for allowing us make use of their animal house for this research and also appreciate members of

staff of Department of Anatomy, Osun State University for their Tutelage.

### Conflict of interest

The authors declare no conflict of interest

### Funding

All expenses for this research were from personal contribution from authors.

### References

Adelakun, S. A., Omotoso, O. D., & Aniah, J. A. (2018). Modulating role of d-ribose-l-cysteine on oxidative stress in streptozotocin induced diabetes on plasma lipoprotein, oxidative status, spermatogenesis and steroidogenesis in male wistar rats. *Curre Res Diabetes & Obes J.*, 9(2), 1-7.

Akang, E. N., Oremosu, A. A., Osinubi, A. A., Dosumu, O. O. & Kusemiju, T. O. (2015). Histomorphometric studies of the effects of *Telfairia occidentalis* on alcohol-induced gonado-toxicity in male rats. *Toxicology Reports*, 2, 968-975.

Anim, J. T., Kehinde, E. O., Prasad, A., & Varghese, R. (2005). Morphological responses of the rabbit testis to ischemic/ reperfusion injury due to torsion. *Urology International*, 75, 258 – 263.

Cuervo JL, Grillo A, Vecchiarelli C, Osio C, & Prudent L. (2007). Perinatal testicular torsion: a unique strategy. *J Pediatr Surg.* 42: 699-703.

Dare B. J, Olayemi O.S, Falana B.A, Duru F.I.O, & Osinubi A. A. A. (2017). D-Riboce-LCystein Maintained Testicular Integrity in Rats Model (*Rattus Novergicus*) Exposed to X-Ray. *Cell Biology*, 5(4), 8-44.

Falana B, Opeyemi A, Mulikat O, Abraham O, & Adeoye O. (2017). Effect of D-ribose-L-cysteine on aluminum induced testicular damage in male Sprague-Dawley rats. *JBRA Assisted Reproduction*, 21(2), 94-100.

Gomes, D. O., Vidal, R. R., Foeppel, B. F., Faria, D. F., & Saito, M. (2015). Cold weather is a predisposing factor for testicular torsion in a tropical country. A retrospective study. *Sao Paulo Medical Journal*, 133, 187-190.

Ikebuaso, A. D., Yama, O. E., Duru, F. I. O., & Oyebadejo, S. A. (2012). Experimental Testicular Torsion in a Rat Model: Effects of Treatment with *Pausinystalia Macroceras* on Testis Functions. *Journal of Reprod Infertil.*, 13(4), 218-224.

Kehinde, E. O., Anim, J. J., Mojiminiyi, O. A., & Al-awadi, F., Omu, A. E., Vanghese R. (2005). Significance of determining the point of reperfusion failure in experimental torsion of testis. *International Journal of Urology*, 12, 81-89.

Kent C., Thomas E., Komorowski K., Barry W., & Ralph W., (2015). The Distribution of Serum Albumin in the Rat Testis, Studied by Electron Microscope Immunocytochemistry on Ultrathin Frozen Sections. *Endocrinology.* 116, 1983-1986.

Mirhoseini, M., Fereshteh, T. A., Abbas, A. M., Zahra R. G., & Elmira, G. (2017). Protective effects of melatonin on testis histology following acute torsion-detorsion in rats. *Int J Reprod BioMed.*, 15(3), 141-146.

Olugbenga, M.A., Duru, F.I.O., Ogedengbe, O.O., Ogbodo, & Onyenekwe, L.A. (2012). The effect of l-arginine on contralateral testes following 7200 torsion Detorsion of the ipsilateral testes. *International Journal of Basic, Applied and Innovative Research IJBAIR*, 1(3), 78 – 84

Osinubi, A. A.A., Medubi, L. J., Akang, E. N., Sodiql, L. K., Samuel, T. A, Kusemiju, T. Osolu, J., Madu, D. & Fasanmade, O. (2018). A comparison of the anti-diabetic potential of d-ribose-l-cysteine with insulim and oral hypoglycaemic agents on pregnant rats. *Toxicology Reports*, 5, 832-838.

**Citation:**

Adunfe, O. O., Ubulu, L. U., Tokunbo, O. S., Adeleke, O. S., Iyiola, O. B., Oguntade, A. A., Babatunde, L. B., Ebukhaile, R. O., Abimbola, P. T., & Duru, F. (2025). Testicular Rescue Following D-ribose L-cysteine Administration on Torsion-detorsion Injury. *Fountain University Journal of Basic Medical and Health Sciences (FUJBMHES), 1(1), 91 - 100.*